

Surgical Pearls

By Richard T. Braver, DPM

HOW TO CONQUER THE ACCESSORY NAVICULAR BONE

In my experience, the Modified Kidner procedure is one of the most reliable operations for reducing arch pain associated with an accessory navicular bone (a.k.a. os tibial externum). You can also use this procedure to treat a prominence at the inner aspect of the arch, which has been caused by an enlarged navicular bone. The most common patients to visit our office with these problems are between the ages of 8 and 15 and are involved in activities like ice skating, ballet and soccer.

What precipitates the pain? It will usually be caused by rubbing of the skate or other footwear against the prominence. You'll commonly see blisters or a red irritated area. Other symptoms to look for, especially when you're treating an older child or adult, include an area of pain along the posterior tibial tendon of the arch and fatigue of the legs. Typically, these patients are not able to participate in sports for a lengthy period of time or you'll hear them complain of pain and/or soreness after extended activities. Most individuals with a prominent navicular area will have tried accommodating this area with a doughnut pad or adjustments to their skate.

During your clinical exam, you may note erythema to the navicular prominence area and a foot that collapses in stance. While it's common to see flat feet with these patients, this may not always be the case. You will note a significant difference in the off-weightbearing arch compared to the foot in stance, which is lower. These patients will always have pain to the navicular bone, especially at the major insertion of the posterior tibial tendon just proximal and also inferior to the navicular bone. You may also find they have pain on resisted adduction.

It is important to examine the posterior tibial tendon and measure the extent of pain to this tendon proximal to the navicular bone. You can clinically determine the amount of posterior tibial tendon involvement by assessing the degree of swelling, pain on palpation and strength. To evaluate the patient's strength, have the patient stand and balance on one foot along with rising up on his or her toes.

Usually, you will only need an X-ray to determine the size or type of the acces-

sory navicular bone or the amount of medial navicular tuberosity hypertrophy. Be cognizant of stress fractures which may be duplicated as a hairline fracture or increased calcification. When treating children, always look for avascular necrosis of the navicular (Kohler's disease). An X-ray of this condition will reveal a flattening of the navicular along with increased bone density.

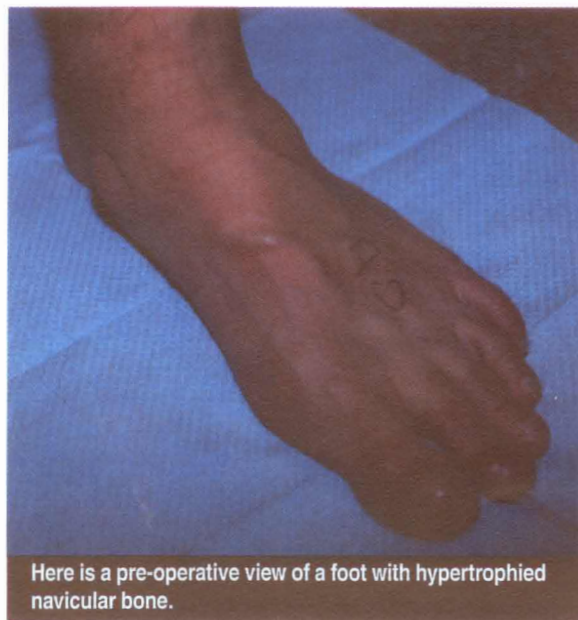
Keep in mind there are two different types of accessory navicular bones, which you can distinguish by getting a weight-bearing AP X-ray of the foot. Dwight has classified type I as a small, round and discreet accessory bone just proximal to the main navicular bone. Geist described the type II accessory bone, which is closely related to the body of the navicular but separated by an irregular plate of dense fibro-cartilage.

What Causes The Painful Arch?

Perhaps the most common of the extra bones in the foot, the accessory navicular bone is estimated to be present in 7 to 19 percent of the population. Zadek and Gold maintained that the bone persisted as a distinct, separate bone in 2 percent of the population. Also be aware that the accessory bone normally fuses completely or incompletely to the navicular. It is this incomplete fusion which allows for micromotion, which, in turn, may cause degenerative changes that can also contribute to the pain.

Looking at the pathomechanics of the enlarged or accessory navicular bone area, it is commonly believed that the posterior tibial tendon loses its vector of pull to heighten the arch. As the posterior muscle contracts, the tendon is no longer pulling straight up on the navicular but must course around the prominence of bone and first pull medially before pulling upward.

In addition, the enlarged bones may irritate and damage the insertional area of the posterior tibial



Here is a pre-operative view of a foot with hypertrophied navicular bone.

tendon, making it less functional. Therefore, the presence of the accessory navicular bone does contribute to posterior tibial dysfunction.

Know The Differences Between The Procedures

The original procedure advocated by Kidner involved shelling out of the accessory navicular bone from within the insertional area of the posterior tibial tendon and rerouting this tendon under the navicular bone in hopes of restoring a normal pull of this tendon. When treating younger children, history has shown us that simply shelling out of the accessory navicular bone from within the tendon and remodeling the tuberosity of the navicular bone can give you satisfactory results.

In general, you want to reserve advancement of the posterior tibial tendon for adults or those who have a more significant flatfoot deformity. You may also use this approach after determining that quality custom orthotics are only resulting in a slight decrease of symptoms.

Step-By-Step Surgical Pointers

Apply a well-padded ankle tourniquet. After the patient is under IV sedation or general anesthesia, perform a posterior tibial nerve block along with local infiltration in a diamond shape around the navicular bone. Mark the most prominent aspect of the navicular bone and outline the course of the posterior tibial tendon.

Make a linear longitudinal incision along the horizontal midline of the navicular bone, extending approximately 2 cm distal and 5 cm proximal. Mildly angle the proximal cut upward following the course of the posterior tibial tendon. Look out for the great saphenous vein and saphenous nerve, which should be dorsal to the surgical area.

Proceed to use a Metzenbaum scissor to dissect subcutaneous tissues away from the capsule of the talar navicular area. Then make a horizontal incision through the capsule directly over the midline of the navicular down to bone. Reflect the navicular joint capsule both superiorly and

inferiorly. You should retract the abductor hallucis plantarly and it may be necessary to use a key periosteal elevator to reflect the capsular tissues from the navicular bone. During the deeper dissection, it also is important to avoid incizing through the posterior tibial tendon.

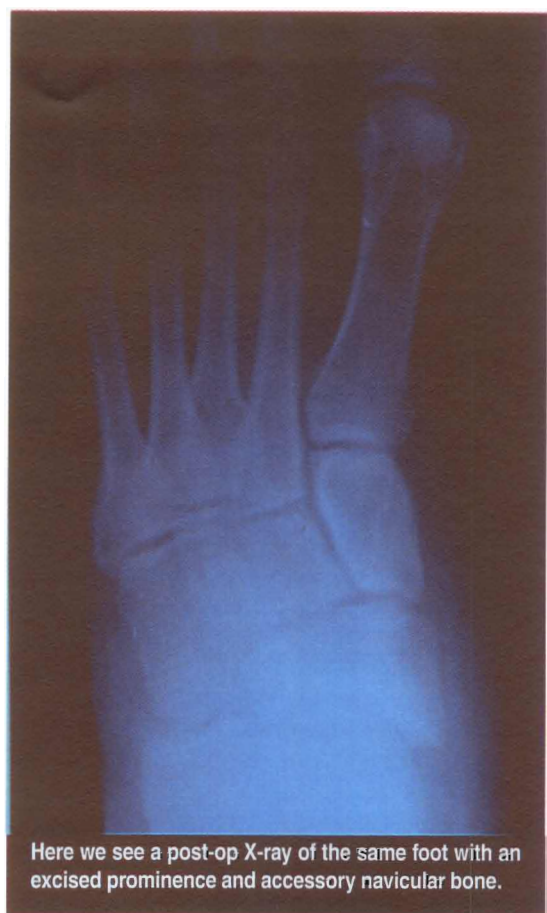Using an osteotome and mallet, proceed to resect the hypertrophied portion of the navicular tubercle (which is prominent medially) from distal to proximal. (Getting pre-operative measurements from the AP X-ray will help you determine how much bone you'll need to remove.) At this time, you can more easily identify the accessory navicular bone proximal to the navicular by its articulation or separation from the larger navicular bone. You can sharply excise the accessory bone with a scalpel or crown and collar scissors.

Examine the posterior tibial tendon by performing a tenolysis proximally until the tendon appears normal in size, continuity and color. Excise any areas of degenerated or abnormal posterior tendon prior to performing tubularization. Then tubularize the frayed or thinned areas distally with 3-0 non-absorbable suture.

When You Should Perform The Modified Kinder Procedure

If you've removed a large portion of hyper-

trophied navicular bone, you may notice redundant posterior tibial tendon. In addition, when you're treating severe flatfoot cases or patients with inherent ligamentous laxity, be aware of excessive laxity of the posterior tibial tendon. It is important to check the redundancy or laxity of the tendon with the foot held in subtalar joint (STJ) neutral position. In these cases, you should perform tendon advancement.



Here we see a post-op X-ray of the same foot with an excised prominence and accessory navicular bone.

What You Should Know About Ancillary Procedures

Kee in mind that excising the accessory navicular bone and advancing the posterior tibial tendon in the symptomatic flat foot may require additional procedures to correct sagittal, transverse and frontal plane motion.

When it comes to controlling excessive motions, common procedures include a subtalar joint arthroereisis, such as the MBA implant. In addition, performing the Cobb procedure (using a portion of the anterior tibial tendon) helps support the navicular bone and reduces the workload of the posterior tibial tendon.

The Evans distal calcaneal wedge osteotomy is advantageous in cases of excessive transverse plane motion, especially when your patient has excessive abduction of the foot. However, you should do this prior to the Kidner type of procedure, as the Evans procedure causes even greater slack within the posterior tibial tendon insertion.

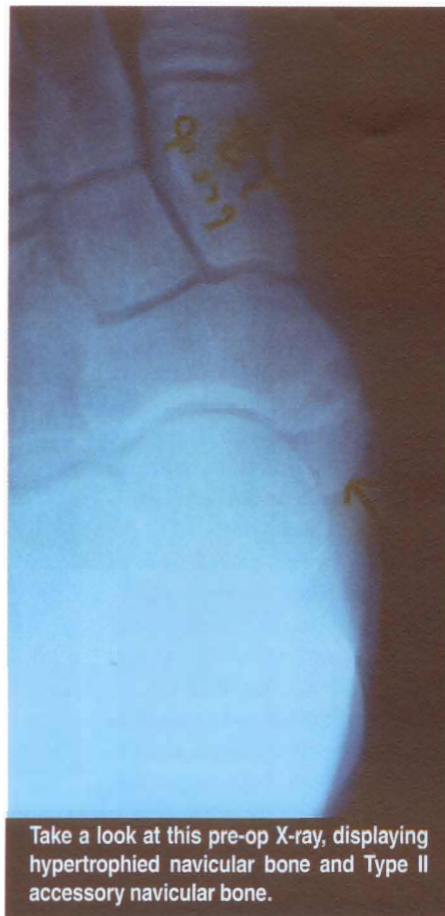
You may also find it necessary to do calcaneal osteotomies to rebalance the foot. This is usually the case with flexible flatfoot deformities. When you run into more rigid flatfoot or arthritic flatfoot deformities, especially those you see in adults, you would need to employ more of the arthrodesis type procedures.

Before you begin, be sure to free the under surface of the navicular bone of soft tissues and rasp the area smooth. Doing so will help facilitate the tenodesis. I prefer to use the Mitek super anchor to assist in a tenodesis. When using the Mitek drill with a measured stop, you drill from medial to lateral directly into the middle of the navicular body. Use the non-absorbable suture attached to the anchor to advance and tack down the posterior tibial tendon plantarly and medially to the navicular bone. While performing the advancement tenodesis, it is important to maintain the foot in STJ neutral or a mildly inverted position.

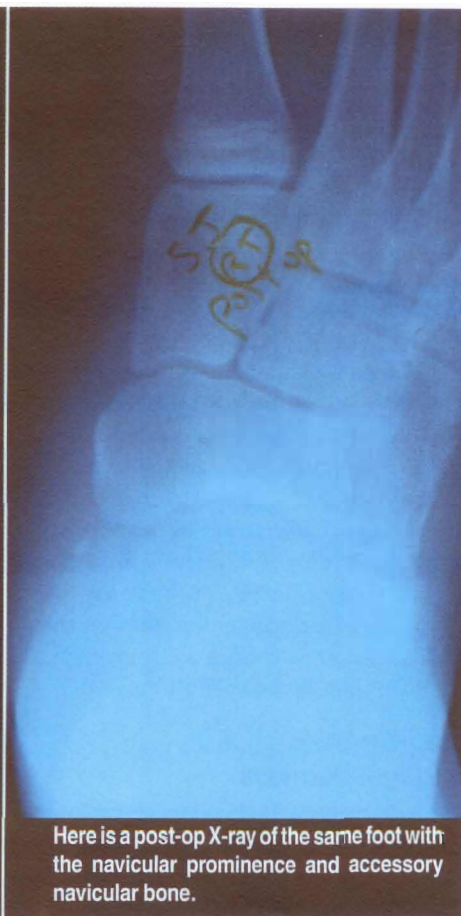Be aware that the two-drill hole method is an alternative to using an anchor to tenodesis the posterior tibial tendon to the navicular bone. Employing a .062 K-wire or small drill bit, make a hole from dorsal to plantar at the medial edge of the navicular bone. Create a second drill hole just proximal to this drill hole. Then thread a 2-0 non-absorbable suture through the proximal drill hole from plantar to dorsal with a Swanson wire passer loop or similar instrument.

The free end of the suture is now on the dorsal aspect of the navicular bone and the needle is at the plantar aspect of the navicular bone. Pass a Bunnell type suture repeatedly through the posterior tibial tendon from distal to proximal and then back proximally. Then cut the needle from the suture. Again, using the Swanson wire passer loop, thread the free end up through the distal hole from plantar to dorsal.

Then pull the suture and tendon tight towards the distal hole. Tie the ends of the suture dorsally by hand while holding the foot in subtalar joint neutral or a mildly inverted position. You may perform additional reinforcing sutures with a 2-0 absorbable, tight-



Take a look at this pre-op X-ray, displaying hypertrophied navicular bone and Type II accessory navicular bone.



Here is a post-op X-ray of the same foot with the navicular prominence and accessory navicular bone.

ening the posterior tibial tendon to plantar soft tissues, including the plantar talo-navicular spring ligament.

Final Notes

Closure includes realigning the periosteum over the navicular bone and suturing with a 3-0 dexton. Reunite the tendon sheath and close with a 5-0 absorbable suture in a continuous baseball suturing technique. Close subcutaneous tissues with a 4-0 absorbable suture. Perform skin closure with a 5-0 absorbable suture in subcuticular suturing technique. Dress the surgical site in typical fashion.

Proceed to apply a well-padded, below knee fiberglass cast with the foot held in STJ neutral or a mildly inverted position. You should have the patient wear the non-weightbearing cast for approximately three weeks and then progress to

partial weightbearing with a cast boot walker. In about four weeks, your patient should start physical rehabilitation and be ambulatory in sneakers. In about three months, he or she should be able to resume exercise activities.

References

1. Macnicol, M.F., Voutsinas S.; Surgical Treatment of the Symptomatic Accessory Navicular, J.B.J.S. Journal of Bone and Joint Surgery, Volume 66-B, Pp. 218-226 March 1984.

Dr. Braver (shown at below) is board certified in foot and ankle surgery by the American Board of Podiatric Surgery. A Fellow of the American College of Foot and Ankle Surgeons, he practices in Englewood, NJ.



Seven to 19 percent of the population may have the accessory navicular bone.